

See discussions, stats, and author profiles for this publication at: <https://www.researchgate.net/publication/221814921>

# Cerebral metabolic changes in men after chiropractic spinal manipulation for neck pain

Article in *Alternative therapies in health and medicine* · November 2011

Source: PubMed

---

CITATIONS

14

---

READS

1,391

9 authors, including:



**Manabu Tashiro**

Tohoku University

262 PUBLICATIONS 3,834 CITATIONS

SEE PROFILE



**Mehedi Masud**

North South University

13 PUBLICATIONS 133 CITATIONS

SEE PROFILE



**Kazuhiko Yanai**

Tohoku University

560 PUBLICATIONS 10,492 CITATIONS

SEE PROFILE

Some of the authors of this publication are also working on these related projects:



PET molecular imaging [View project](#)

ORIGINAL RESEARCH

# Cerebral Metabolic Changes in Men After Chiropractic Spinal Manipulation for Neck Pain

Takeshi Ogura, DC, PhD; Manabu Tashiro, MD, PhD; Mehedi Masud, MD, PhD; Shoichi Watanuki; Katsuhiko Shibuya, MS; Keiichiro Yamaguchi, MD, PhD; Masatoshi Itoh, MD, PhD; Hiroshi Fukuda, MD, PhD; Kazuhiko Yanai, MD, PhD

## Abstract

**Background** • Chiropractic spinal manipulation (CSM) is an alternative treatment for back pain. The autonomic nervous system is often involved in spinal dysfunction. Although studies on the effects of CSM have been performed, no chiropractic study has examined regional cerebral metabolism using positron emission tomography (PET).

**Objective** • The aim of the present study was to investigate the effects of CSM on brain responses in terms of cerebral glucose metabolic changes measured by [<sup>18</sup>F]fluorodeoxyglucose positron emission tomography (FDG-PET).

**Methods** • Twelve male volunteers were recruited. Brain PET scanning was performed twice on each participant, at resting and after CSM. Questionnaires were used for subjective evaluations. A visual analogue scale (VAS) was rated by participants

before and after chiropractic treatment, and muscle tone and salivary amylase were measured.

**Results** • Increased glucose metabolism was observed in the inferior prefrontal cortex, anterior cingulate cortex, and middle temporal gyrus, and decreased glucose metabolism was found in the cerebellar vermis and visual association cortex, in the treatment condition ( $P < .001$ ). Comparisons of questionnaires indicated a lower stress level and better quality of life in the treatment condition. A significantly lower VAS was noted after CSM. Cervical muscle tone and salivary amylase were decreased after CSM.

**Conclusion** • The results of this study suggest that CSM affects regional cerebral glucose metabolism related to sympathetic relaxation and pain reduction. (*Altern Ther Health Med.* 2011;17(6):12-17.)

**Takeshi Ogura, DC, PhD**, is a research fellow in the Division of Cyclotron Nuclear Medicine, Cyclotron and Radioisotope Center, Tohoku University, Sendai, Japan, and a director at the Japan Chiropractic Doctor College, Sendai. **Manabu Tashiro, MD, PhD**, is an associate professor and a chief nuclear medicine physician; **Mehedi Masud, MD, PhD**, is a research fellow; **Shoichi Watanuki** is a radiological technologist in the Division of Cyclotron Nuclear Medicine, Cyclotron and Radioisotope Center. **Masatoshi Itoh, MD, PhD**, is a specially-approved visiting professor in the Division of Cyclotron Nuclear Medicine, Cyclotron and Radioisotope Center, and a director at Sendai Medical Imaging Clinic, Sendai, Japan. **Keiichiro Yamaguchi, MD, PhD**, is a visiting professor in the Division of Cyclotron Nuclear Medicine, Cyclotron and Radioisotope Center, and a director at the Advanced Image Medical Center, Sendai Welfare Hospital. **Katsuhiko Shibuya, MS**, is a researcher and **Kazuhiko Yanai, MD, PhD**, is a professor in the Department of Pharmacology, Graduate School of Medicine, Tohoku University. **Hiroshi Fukuda, MD, PhD**, is a professor at the Department of Radiology and Nuclear Medicine, the Institute of Development, Aging and Cancer, Tohoku University.

Corresponding Author: Manabu Tashiro, MD, PhD  
E-mail: [mtashiro@cyric.tohoku.ac.jp](mailto:mtashiro@cyric.tohoku.ac.jp)

Chiropractic spinal manipulation (CSM) is an alternative treatment for ailments such as neck, back, and lower back pain. For >100 years, chiropractors have asserted that overall health can be improved through spinal manipulative therapy.<sup>1-5</sup> Research on CSM has been extensively performed worldwide, and its efficacy on musculoskeletal symptoms has been well documented. The autonomic nervous system has been invoked in constructing mechanisms that account for the effect of spinal dysfunction.<sup>6</sup> Previous studies documented a potential relationship between the vertebral subluxation complex and the function of the autonomic nervous system.<sup>1,6-13</sup> These studies mainly discussed the autonomic effects on cardiovascular function in relation to CSM.<sup>9,11-13</sup> A recent study using heart rate variability analysis documented that chiropractic adjustment affects the autonomic nervous system.<sup>13</sup> However, literature search showed no study using positron emission tomography (PET) to examine regional cerebral metabolic changes related to autonomic responses resulting from CSM.

Only one available neuroimaging study on CSM using single photon emission computed tomography (SPECT) indicated decreased regional cerebral blood flow in the left cerebellum related to adverse reactions after treatment.<sup>14</sup> Since this study focused on the adverse reactions, the brain effects and the clinical effects of CSM have remained unknown. Recent chiropractic research documented the need for a functional neuroimaging study regarding the effects of spinal manipulation for deeper understanding of the neu-

rophysiological effects of CSM.<sup>15</sup> Thus, we hypothesized that one CSM might induce metabolic increase or decrease (activation or deactivation) in the brain regions associated with autonomic nervous functions in response to CSM intervention: the limbic and paralimbic regions such as prefrontal cortex, orbitofrontal cortex, cingulate gyrus, striatum and thalamus, cerebellum, and brain stem.

Functional neuroimaging techniques are powerful tools to investigate neuronal activity in the human brain.<sup>15</sup> The PET scan has been used for measuring regional cerebral blood flow and regional cerebral metabolic rate using radiolabeled molecules, which are either injected intravenously or continuously inhaled by the participant.<sup>15-21</sup> In the research setting, functional neuroimaging has been used in studies of acute brain activation, and for this purpose, functional magnetic resonance imaging (fMRI) has replaced PET with [<sup>15</sup>O]H<sub>2</sub>O because of its preferred spatial resolution, avoidance of radioactive materials, and operating cost per investigation.<sup>15,18,19</sup> However, PET with <sup>18</sup>F-labeled fluorodeoxyglucose (FDG) has been regarded as an excellent imaging marker of brain metabolic activity (glucose consumption).<sup>20</sup> The molecule FDG, a radioactive analogue of glucose, is trapped metabolically into activated cells in the brain and can be substantially used for evaluating physiological and biomechanical functions *in vivo*.<sup>21</sup> Initially, this technique was used in healthy volunteers who performed a natural running task in upright posture.<sup>22</sup> Later, this technique was applied to daily movement<sup>23</sup> and alternative therapy such as aromatherapy.<sup>24</sup> An important advantage of the FDG technique is that the regional brain activity during 30 minutes after injection is averaged and recorded based on the biochemical property of “metabolic trapping,”<sup>21</sup> where the phases for FDG uptake and for PET measurement can be separated (Figure 1). Another advantage of this technique is low radiation exposure achieved by a sensitive 3-dimensional data acquisition mode.<sup>21</sup>

We hypothesized that a CSM treatment might induce metabolic increase or decrease (activation or deactivation) in the brain regions associated with autonomic nervous functions in response to CSM intervention: the limbic and paralimbic regions such as prefrontal cortex, orbitofrontal cortex, cingulate gyrus, striatum and thalamus, cerebellum, and brain stem. The aim of the present study was to investigate the effects of CSM on brain responses in terms of cerebral glucose metabolic changes using PET and FDG. In addition, we evaluated the relation between the results of PET investigation and the changes in autonomic function and pain intensity induced by chiropractic treatment.

## METHODS

### Participants and Materials

Volunteer men with cervical pain and shoulder stiffness were recruited after researchers placed a poster on the campus of Tohoku University. Included were men aged 20 to 40 years with cervical pain and shoulder stiffness who did not receive any kind of manipulative treatment for ≥1 month before the experiment. Exclusion criteria were (1) the presence of disc problems such as disc herniation or significant disc degeneration and (2) any other physical or mental disorders or medication that might affect brain function or perfusion. After giving informed consent, all 15 candidates were first assigned for MRI examination of the cervical region, and 3 partici-

FIGURE 1

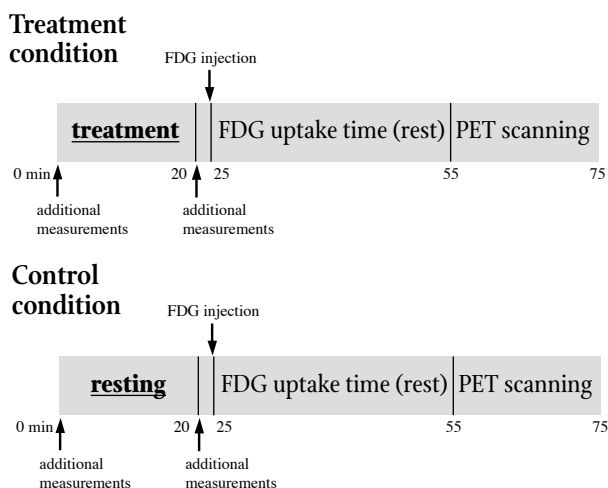
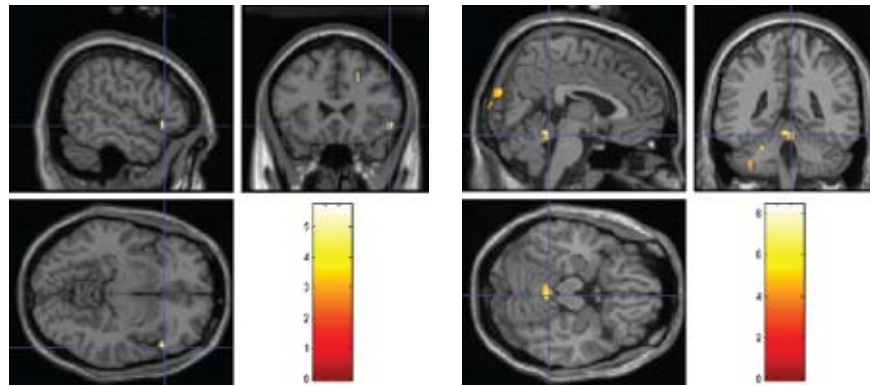


Diagram demonstrating the present protocol. In the treatment or control (resting, no treatment) condition, <sup>18</sup>F-labelled fluorodeoxyglucose (FDG) was injected shortly after the chiropractic treatment or resting period. Additional measurements such as muscle stiffness, salivary amylase, and subjective feelings were made before and after the treatment or resting period. The duration of 30 minutes after FDG injection is FDG uptake time in the resting state. Positron Emission Tomography (PET) scanning started 30 minutes after FDG injection and continued for 20 minutes. In the treatment condition, FDG was injected shortly after the treatment. Additional measurements such as muscle stiffness, salivary amylase, and subjective feeling were conducted before and after the treatment. The duration of 30 minutes following FDG injection is FDG uptake time in the resting state. PET scanning started 30 minutes after FDG injection and following 20 minutes.

pants with disc problems were excluded from the study. Medical screening was performed to confirm absence of any disorders or medication that might affect brain function. Therefore, 12 men volunteers aged 21 to 40 years (mean age ± SD, 28 ± 7 y) were included in the study. Women were not included because of the higher risk of radiation exposure to the ovary and the physiological fluctuation of the brain activity associated with the menstrual cycle. The present study protocol was approved by the Ethics Committee of Tohoku University Graduate School of Medicine, Sendai, Japan (No. 2008-115).

The present study was conducted in crossover study design, in which each participant was examined twice (once in the “treatment” and the other time in the “control” [“resting”] conditions) to compare resting regional brain activity in the 2 conditions (Figure 1). In the treatment condition, participants received a single CSM intervention including a CMS diagnostic procedure (in total 20 minutes). Shortly after the CSM treatment, FDG-containing saline solution was injected into the participant through the left antecubital vein (37 MBq) in a quiet, dimly lit room. Participants were asked to sit in a relaxed manner with their eyes closed for 30 minutes before the scan. The brain scan was initiated 30 minutes after the FDG injection using a PET scanner (SET2400W, Shimadzu Inc, Kyoto, Japan). The PET scan covered the entire brain in 1 scan, tak-



**FIGURE 2**

Regional activation (left) and deactivation (right) after chiropractic spinal manipulation. Brain regions showing a metabolic increase (left) and a metabolic decrease (right) in the treatment condition. Both images show results of voxel-by-voxel comparison of regional cerebral glucose metabolic images using statistical parametric mapping (SPM) (height threshold:  $P < .001$ , extent threshold: 10 voxel minimum).

ing 10 minutes for the emission scan and another 5 minutes for the transmission scan for tissue attenuation correction (Figure 1). In the scan for the control condition, FDG was injected into the participant after a 20 minute resting phase instead of CSM intervention; the scanning procedure following was identical to that for the treatment condition (Figure 1). The radiation exposure from 1 PET scan in this study was estimated at approximately 0.9 mSv; this was comparable to the exposure from a chest radiograph (0.4 mSv per test) and less than annual environmental exposure (2.4 mSv).<sup>21</sup>

The order of the 2 scans—that is, “control–treatment” and “treatment–control”—was counterbalanced to minimize an “order effect.” Order effect occurs because study participants tend to feel psychophysiological stress more in the first scan than in subsequent scans. Therefore, the protocol was prepared to minimize this order-associated effect. As a result, the first scan was performed in the treatment condition in half of the participants and vice versa. The interval between the first and second scans was  $\geq 1$  week to eliminate residual effects of treatment; the interval between conditions (scans) ranged from 1 to 6 weeks (mean interval  $\pm$  SD,  $22 \pm 13$  d). The CSM was performed by the same chiropractor, an advanced proficiency-rated doctor of activator methods.

Questionnaires were used for subjective evaluation. Participants were requested to answer questions related to the Stress Response Scale (SRS-18) and European Organization for Research and Treatment of Cancer Quality of Life Questionnaire-Core 30 (EORTC QLQ-C30) immediately after the CSM treatment and before FDG injection. Results of SRS-18 and EORTC QLQ-C30 were examined using Wilcoxon signed-rank test for statistical analysis. In addition, intensity of subjective pain sensation was evaluated using a visual analogue scale (VAS) (0, no pain; 10, maximum possible pain) before and after CSM intervention. Wilcoxon signed-rank test was performed for analysis of the VAS results, as well. Cervical muscle tone was measured bilaterally at the superior part of the trapezius muscle (Muscle Meter PEK 1, Imoto Inc, Kyoto, Japan). Salivary amylase was determined (Amylase Monitor, Nipro Inc, Osaka, Japan) as a measure of changes in autonomic nervous system function. The measurements of muscle tone and salivary amy-

lase were performed before and after the 20-minute treatment or resting phase (Figure 1). Paired t tests were performed on measurements of muscle tone and salivary amylase to determine differences in before and after measurements between the resting and treatment conditions.

#### **<sup>18</sup>F-labelled Fluorodeoxyglucose Positron Emission Tomography**

The PET brain images were analyzed to identify regional changes in glucose metabolic rate using a software package Statistical Parametric Mapping 2 (SPM2, Functional Imaging Laboratory, London, United Kingdom).<sup>25,26</sup> Positional errors between the two scans were corrected for each participant, using the realignment function of the SPM2. The FDG brain template (Montreal Neurological Institute, McGill University, Canada)<sup>25</sup> was used for anatomical standardization (spatial normalization) of the PET images by applying linear and nonlinear transformations, which minimized the intersubject differences in gyral and functional anatomy. The size of each voxel is converted into 2 mm (for x, y, and z axes) in the normalized image. The normalized data were smoothed using isotropic Gaussian kernel of 12 mm (for x, y, and z axes) to increase the signal-to-noise ratio by suppressing high frequency noise in the images.

Voxel-by-voxel analysis (such as Statistical Parametric Mapping) is the standard tool for detecting regional changes in radioactivity levels in certain brain regions. The most popular contrast in these studies has been to contrast “resting” with “task or stimulus.” For statistical analysis, all voxel values were normalized to an arbitrary global mean value of 50 mg/100 mL/min by analysis of covariance to exclude the effects of intersubject variability in global cerebral glucose metabolism. A paired t test was applied to each voxel; only voxel clusters were maintained with voxels corresponding to  $P < .001$  in a single test (height threshold for voxel values) in 2 ways.<sup>26</sup> Usually, statistically significant voxels tend to appear in a group since each neural substructure has a certain volume in human brain (eg anterior cingulate cortex). The size of the voxels group (cluster size) is described by the number of voxels showing statistical significance together. Based on the fact that each

neural substructure has a certain volume, a very small cluster with just a few voxels is not physiological and often produced by noises in images. Thus, an extent threshold for the voxel cluster size is additionally defined (10 to 50 voxels minimum).<sup>26</sup> The statistical significance of a regional metabolic change was given in z scores. The z score value was the difference between the treatment and control group mean values, divided by standard deviation of the control values  $[(\text{Mean}_{\text{treatment}} - \text{Mean}_{\text{control}}) / \text{SD}_{\text{control}}]$ . Empirically in Statistical Parametric Mapping analysis, a z score higher than 3.0 (approximately corresponding to  $P < .001$ ) was considered statistically significant. The location of each statistical peak was identified based on a coplanar stereotaxic atlas of the human brain.<sup>27</sup> In the stereotaxic atlas, the location of statistical peak is described in x,y,z axes of the stereotaxic coordinates of the standardized human brain space. Each location is also classified into a brain area called Brodmann's area (BA) defined by its histological similarity that also suggests functional similarity.<sup>27</sup> Statistically significant areas were superimposed on the standard MRI brain template images (Figure 2).

**RESULTS**

The FDG-PET analysis revealed changes in regional cerebral metabolism between resting and treatment ( $P < .001$ ). In the treatment condition, increased glucose metabolism was observed in the inferior prefrontal cortex (BA 47), anterior cingulate cortex (BA 32), and middle temporal gyrus (BA 21); decreased glucose metabolism was observed in the cerebellar vermis and visual association cortex (BA 19) (Table 1).

Results of subjective measures revealed significant differences between the resting and treatment conditions. The mean SRS-18 score was significantly lower in the treatment than the resting condition (Table 2). The mean EORTC QLQ-C30 score was also significantly lower in the treatment than resting condition (Table 2). Comparisons of mean VAS showed that pain was significantly improved after treatment (Table 2). Measurements of cervical mus-

**TABLE 1** Activation/Deactivation Areas After Chiropractic Spinal Manipulation in Men (n=12)

	Anatomical Region	Coordinates x, y, z (mm)	Brodman's Area (BA)	Cluster Size	z score
Activation	IPC	54 24 -8	47	19	3.82
	MTG	-48 -36 0	21	30	3.73
	ACC	22 24 38	32	10	3.48
Deactivation	CV	4 -42 -18		121	4.62
	VAC	4 -90 24	19	46	3.64

The table indicates results of voxel-by-voxel analysis using statistical parametric mapping 2 (SPM2). Regions of statistically significant activation and deactivation are demonstrated. The location of these statistic peaks in each regions is described by the x, y, and z coordinates in stereotaxic standard brain space and by the Brodmann's area. Cluster size indicates the number of voxels in each region showing statistical significance simultaneously. The z score indicates statistical significance if it is >3.0, corresponding to  $P < .001$  (without corrections for multiple comparisons).  
Abbreviations: IPC, inferior prefrontal cortex; MTG, middle temporal gyrus; ACC, anterior cingulate cortex; CV, cerebellar vermis; VAC, visual association cortex.

cle tone showed significant improvements from the resting to treatment conditions (Table 2). A significant decrease in mean salivary amylase was observed after chiropractic treatment (Table 2).

**DISCUSSION**

In the present study, participants had cervical pain at the time of the examination as commonly experienced by many chiropractic patients. Psychological stress may be a cause of cervical pain, and diagnosis and management of cervical pain routinely includes psychological stress management<sup>28-33</sup> because psychological stress

**TABLE 2** Results of Questionnaires and Measurements in Subjects Having Chiropractic Spinal Manipulation

	Resting		Treatment		P Value
SRS-18	10.4±8.3		5.2±5.3		.003
EORTC QLQ-C30	45.1±8.8		42.0±8.8		=.016
	Before	After	Before	After	
VAS			3.6±1.7	1.1±1.1	<.001
Muscle tone (mm)					
Right	56.8±3.3	56.3±3.7	57.3±4.4	51.1±4.8	<.002
Left	58.8±2.4	57.8±3.0	58.8±3.7	53.7±3.5	<.001
Salivary amylase (KIU/L)	32.3±29.8	43.1±36.9	27.0±19.2	19.5±12.4	<.04

Data reported as mean ±SD. Abbreviations: SRS-18, Stress Response Scale-18; EORTC QLQ-C30, European Organization for Research and Treatment of Cancer Quality of Life Questionnaire-Core 30; VAS, visual analogue scale  
Muscle tone—differences between before and after measurements: Right: resting, 0.5±2.9 mm; treatment, 6.1±4.3 mm;  $P < .005$ . Left: resting, 1.1±1.8 mm; treatment, 5.1±2.5 mm;  $P < .001$ .  
Salivary amylase: differences between the means of the before and after measurements: resting, -10.8±19.5 KIU/L; treatment, 7.5±17.0 KIU/L;  $P < .05$ .



causes sympathetic activation.<sup>34-36</sup> Therefore, it is possible to compare autonomic function in the resting and treatment conditions in patients who have cervical pain. However, the usefulness of CSM for cervical pain is controversial because of possible adverse reactions of cervical adjustment, including a significant increase in neck pain and stiffness and occasional headaches or radiating pain.<sup>37,38</sup> Therefore, we selected Activator Methods as the treatment procedure in the present study. Activator Methods are a form of research-based spinal manipulative therapy<sup>39</sup> in which high-velocity and relatively low force-impact instruments known as Activator Adjusting Instruments are used.<sup>40</sup> Activator Adjusting Instruments are in use by >50% chiropractic practitioners.<sup>40,41</sup> In addition, investigations on Activator Adjusting Instruments have been performed because of safety concerns related to general cervical manipulation<sup>39,40,42,43</sup>; in one study, Activator Adjusting Instruments maximized therapeutic effects and benefits and decreased the risk of iatrogenic injury.<sup>40</sup>

In previous studies aiming at scientific examination of the autonomic effects of CSM intervention, cardiovascular function and subjective feeling had been the main outcome measures.<sup>10,12-14</sup> However, it would be useful to examine the status of regional brain activity immediately after the CSM intervention. We first applied the FDG technique for a long-term activation study in healthy volunteers;<sup>21-24</sup> the regional brain activity during 30 minutes after FDG injection was averaged and recorded based on the biochemical property of "metabolic trapping."<sup>21</sup> In the present study, the regional metabolic changes in the limbic and paralimbic regions, cerebellum, and brain stem were expected.

In the present PET investigation, the most significant change was detected in the cerebellar vermis, which was deactivated in the treatment condition compared to the resting condition. The cerebellar vermis may be important in pain perception. Neuroimaging studies have shown a pattern in cerebellar activation during the pain response.<sup>44-46</sup> Glucose metabolic changes have been noted in the cerebella of 13 of 18 patients suffering regional pain syndrome,<sup>47</sup> and other authors have noted a similar activation pattern in the cerebellum.<sup>47,48</sup> In the present study, all participants had neck pain at the time of the experiment, and the results of VAS indicated a significantly lower value after CSM. Thus, deactivation of the cerebellar vermis in this study may be related to pain reduction in the participants. The cerebellar vermis is also concerned with mental stress. Painful heat activates the anterior cerebellum around the vermis, and a sensory cue that anticipates the painful stimulation results in activation of the posterior cerebellar vermis.<sup>45,46</sup> In addition, the cerebellar vermis is involved with the autonomic nervous system. Previous studies have suggested that the cerebellum is involved in the regulation of autonomic responses in aversive conditioning.<sup>44,49,50</sup> Removal of the cerebellum impairs performance of autonomic functions including salivary, cardiac, and respiratory conditioning.<sup>44,49,50</sup> These effects on aversive conditioning can be localized to the cerebellar vermis.<sup>44</sup> Stimulation of the cerebellar vermis, not the hemispheres, inhibits vasomotor tone previously increased by peripheral stimulation.<sup>44,51</sup> Thus, deactivation of the cerebellar vermis in the present study may have been related to a decrease in sympathetic tone. Mental stress causes sympathetic activation,<sup>34-36</sup> and stress-related disorders are frequently accompanied by increased sympathetic activity and muscle tone.<sup>34</sup> Some studies

have shown that chronic activation of the sympathetic nervous system in chronic stress facilitates tonic and painful muscle contractions, as has been suggested for chronic tension-type headaches and work-related myalgia.<sup>34,52,53</sup> In the present study, measurement of muscle tone indicated a significantly lower value after CSM at which point the cerebellar vermis was deactivated. Therefore, we suggest that deactivation of the cerebellar vermis may be preceded by decreases in sympathetic tone, muscle tone, and pain.

The anterior cingulate cortex, inferior prefrontal cortex, and middle temporal gyrus were activated in the treatment condition in the present study. The cingulate cortex is involved in the generation of autonomic responses,<sup>34,54,55</sup> and performance of relaxation tasks may elicit maximal activation in the anterior cingulate region.<sup>56</sup> This region of the limbic cortex has been implicated in cognitive and emotional processing and as part of the midline attentional system that involves the dorsolateral prefrontal cortex.<sup>56-58</sup> The lateral prefrontal regions are deactivated during various cognitive tasks compared to resting.<sup>59-63</sup> It is possible that the lateral prefrontal regions are activated during the relaxed condition. Activation of the inferior prefrontal cortex in the treatment condition may indicate a relaxation effect. Thus, the results of the present study suggest that activation of the anterior cingulate cortex and inferior prefrontal cortex may arise from sympathetic relaxation.

Measurement of salivary amylase in the present study revealed significantly lower values after CSM and increased values in the resting condition. Salivary measures have become increasingly important in psychoneuroendocrinological research on stress.<sup>64</sup> A parameter of salivary measures thought to reflect stress-related changes in the body is the salivary enzyme alpha-amylase.<sup>64-68</sup> Authors have documented an increase in salivary amylase in people undergoing psychological stress.<sup>64,65</sup> Thus, it is possible that a decrease in salivary amylase is observed in people in a relaxed condition. Regarding the results of PET analysis, the reduction in salivary amylase in the present treatment condition may be related to activated areas and deactivated areas may be related to sympathetic relaxation.

The limitations of this study include the limited number of participants and absence of a control group, though many clinical PET studies have been done without control groups based on test-retest reproducibility.<sup>69</sup> Furthermore, some of the results in this study are based on subjective evaluations of the participants. An additional limitation is that the chiropractic treatment was performed by a single practitioner. Another disadvantage of this technique would be radiation exposure, though the exposure was as low as reasonably achievable.

## CONCLUSION

In summary, the present study demonstrated sympathetic relaxation and corresponding regional brain metabolic changes, as well as reduced muscle tone and decreased pain intensity following a chiropractic spinal manipulation. FDG-PET seems to be a very promising tool for elucidating the underlying mechanism of clinical effects of the chiropractic treatment. Further neuroimaging studies are needed to support the results because the number of participants was small in the present study.

## Acknowledgements

Authors would like to thank Kazuko Takeda, of the Department

of Cyclotron Nuclear Medicine, Cyclotron and Radioisotope Center, Tohoku University, for her technical support on this study. The authors also would like to thank the Japan Chiropractic Doctor College for its contribution of funding to this study.

## REFERENCES

- Eingorn AM, Muhs GJ. Rationale for effects of manipulative therapy on autonomic tone by analysis of heart rate variability. *J Manipulative Physiol Ther.* 1999;22(3):161-165.
- Palmer DD. *Textbook of the Science, Art and Philosophy of Chiropractic.* Portland, OR: Portland Printing House; 1910.
- Palmer DD. *The Chiropractor.* Los Angeles, CA: Beacon Light Printing Company; 1914.
- Leach RA, Phillips R. *The Chiropractic Theories: A Synopsis of Scientific Research.* 2nd ed. Baltimore, MD: Lippincott Williams and Wilkins; 1986.
- Wardwell WI. *Chiropractic: History and Evolution of a New Profession.* St Louis, MO: Mosby-Year Book; 1992.
- Budgell BS. Reflex effects of subluxation: the autonomic nervous system. *J Manipulative Physiol Ther.* 2000;23(2):104-106.
- Gatterman MI. *Foundations of Chiropractic: Subluxation.* St Louis, MO: CV Mosby; 1995.
- Jarmel ME. Possible role of spinal joint dysfunction on the genesis of sudden cardiac death. *J Manipulative Physiol Ther.* 1989;12(6):469-477.
- Canterbury Spine and Health Practice. Canterbury Health Practice Web site. [www.ideal-spinecentre.co.uk/AZ\\_Chiropractic\\_Cardiovascular.htm](http://www.ideal-spinecentre.co.uk/AZ_Chiropractic_Cardiovascular.htm). Accessed January 9, 2012.
- Slosberg M. Effects of altered afferent articular input on sensation, proprioception, muscle tone and sympathetic reflex responses. *J Manipulative Physiol Ther.* 1988;11(5):400-408.
- Zhang J, Dean D, Nosco D, Strathopoulos D, Floros M. Effect of chiropractic care on heart rate variability and pain in a multisite clinical study. *J Manipulative Physiol Ther.* 2006;29(4):267-274.
- Budgell B, Polus B. The effects of thoracic manipulation on heart rate variability: a controlled crossover trial. *J Manipulative Physiol Ther.* 2006;29(8):603-610.
- Roy RA, Boucher JP, Comtois AS. Heart rate variability modulation after manipulation in pain-free patients vs patients in pain. *J Manipulative Physiol Ther.* 2009;32(4):277-286.
- Cagnie B, Jacobs F, Barbaix E, Vinck E, Dierckx R, Cambier D. Changes in cerebellar blood flow after manipulation of the cervical spine using Technetium 99-Ethyl cysteinate dimer. *J Manipulative Physiol Ther.* 2005;28(2):103-107.
- Lystad RP, Pollard H. Functional neuroimaging: a brief overview and feasibility for use in chiropractic research. *J Can Chiropr Assoc.* 2009;53(1):59-72.
- Sestini S. The neural basis of functional neuroimaging signal with positron and single-photon emission tomography. *Cell Mol Life Sci.* 2007;64(14):1778-1784.
- Kimberley TJ, Lewis SM. Understanding neuroimaging. *Phys Ther.* 2007;87(6):670-683.
- Wintermark M, Sesay M, Barbier E, et al. Comparative overview of brain perfusion imaging technique. *Stroke.* 2005;36(9):e83-e99.
- Hennig J, Speck O, Koch MA, Weiller C. Functional magnetic resonance imaging: a review of methodological aspects and clinical applications. *J Magn Reson Imaging.* 2003;18(1):1-15.
- Phelps ME, Mazziotta JC. Positron emission tomography: human brain function and biochemistry. *Science.* 1985;228(4701):799-809.
- Tashiro M, Itoh M, Fujimoto T, Masud MM, Watanuki S, Yanai K. Application of positron emission tomography to neuroimaging in sports sciences. *Methods.* 2008;45(4):300-306.
- Tashiro M, Itoh M, Fujimoto T, et al. 18F-FDG PET mapping of regional brain activity in runners. *J Sports Med Phys Fitness.* 2001;41(1):11-17.
- Jeong M, Tashiro M, Singh LN, et al. Functional brain mapping of actual car-driving using [18F]FDG-PET. *Ann Nucl Med.* 2006;20(9):623-628.
- Duan X, Tashiro M, Wu D, et al. Autonomic nervous function and localization of cerebral activity during lavender aromatic immersion. *Technol Health Care.* 2007;15(2):69-78.
- Friston KJ, Ashburner J, Frith CD, Poline JB, Heather JD, Frackowiak RS. Spatial registration and normalization of images. *Hum Brain Mapp.* 1995;3(3):165-189.
- Friston KJ, Holmes A, Poline JB, Price CJ, Frith CD. Detecting activations in PET and fMRI: levels of inference and power. *Neuroimage.* 1996;2(3 Pt 1):223-235.
- Talairach J, Tournoux P. *Co-Planar Stereotaxic Atlas of the Human Brain: 3-dimensional Proportional System: An Approach to Cerebral Imaging.* New York, NY: Thieme; 1988.
- Jamison J. Stress: the chiropractic patients' self-perceptions. *J Manipulative Physiol Ther.* 1999;22(6):395-398.
- Weiser S, Cedraschi C. Psychosocial issues in the prevention of chronic low back pain—a literature review. *Baillieres Clin Rheumatol.* 1992;6(3):657-684.
- Linton SJ. An overview of psychosocial and behavioral factors in neck-and-shoulder pain. *Scand J Rehabil Med Suppl.* 1995;32:67-77.
- Minocha A, Joseph AS. Pathophysiology and management of noncardiac chest pain. *J Ky Med Assoc.* 1995;93(5):196-201.
- Waddell G. Biophysiological analysis of low back pain. *Baillieres Clin Rheumatol.* 1992;6(3):523-557.
- Hasenbring M, Marienfeld G, Kuhlendahl D, Soyka D. Risk factors of chronicity in lumbar disc patients. A prospective investigation of biologic, psychologic, and social predictors of outcome. *Spine (Phila Pa 1976).* 1994;19(24):2759-2765.
- Schindwein P, Buchholz HG, Schreckenberger M, Bartenstein P, Dieterich M, Birklein F. Sympathetic activity at rest and motor brain areas: FDG-PET study. *Auton Neurosci.* 2008;143(1-2):27-32.
- Seki S. Autonomic nervous function in patients with vertigo—evaluation for static function, variation and dynamic change using power spectral analysis of RR intervals [article in Japanese]. *Nihon Jibinkoka Gakkai Kaiho.* 1997;100(4):457-466.
- Wood PB. Stress and dopamine: implications for the pathophysiology of chronic widespread pain. *Med Hypotheses.* 2004;62(3):420-424.
- Rosner AL. Adverse reactions to chiropractic care in the UCLA neck pain study: a response. *J Manipulative Physiol Ther.* 2006;29(3):248-251.
- Hurwitz EL, Morgenstern H, Vassilaki M, Chiang LM. Frequency and clinical predictors of adverse reactions to chiropractic care in the UCLA neck pain study. *Spine (Phila Pa 1976).* 2005;30(13):1477-1484.
- Fuhr AW, Menke JM. Status of activator methods chiropractic technique, theory, and practice. *J Manipulative Physiol Ther.* 2005;28(2):e1-e20.
- Keller TS, Colloca CJ, Fuhr AW. Validation of the force and frequency characteristics of the activator adjusting instrument: effectiveness as a mechanical impedance measurement tool. *J Manipulative Physiol Ther.* 1999;22(2):75-86.
- Christensen MG, Delle Morgan DR, National Board of Chiropractic Examiners. *Job Analysis of Chiropractic: A Project Report, Survey Analysis and Summary of the Practice of Chiropractic Within the United States.* Greeley, CO: National Board of Chiropractic Examiners; 1993.
- Hurwitz EL, Aker PD, Adams AH, Meeker WC, Shekelle PG. Manipulation and mobilization of the cervical spine. A systematic review of the literature. *Spine (Phila Pa 1976).* 1996;21(15):1746-1759.
- Terret AG. *Current Concepts in Vertebrobasilar Complications Following Spinal Manipulation.* West Des Moines, IA: NCMIC Group Inc; 2001.
- Sacchetti B, Scelfo B, Strata P. Cerebellum and emotional behavior. *Neuroscience.* 2009;162(3):756-762.
- Ploghaus A, Tracey I, Clare S, Gati JS, Rawlins JN, Matthews PM. Learning about pain: the neural substrate of prediction error for aversive events. *Proc Natl Acad Sci U S A.* 2000;97(16):9281-9286.
- Ploghaus A, Tracey I, Gati JS, et al. Dissociating pain from its anticipation in the human brain. *Science.* 1999;284(5422):1979-1981.
- Shiraishi S, Kobayashi H, Nishihashi T, et al. Cerebral glucose metabolism change in patients with complex regional pain syndrome: a PET study. *Radiat Med.* 2006;24(5):335-344.
- Peyron R, Laurent B, Garcia-Larrea L. Functional imaging of brain response to pain. A review and meta-analysis (2000). *Neurophysiol Clin.* 2000;30(5):263-288.
- Berntson GG, Torello MW. The paleocerebellum and the integration of behavioral function. *Physiol Psychol.* 1982;10(1):2-12.
- Sacchetti B, Scelfo B, Strata P. The cerebellum: synaptic changes and fear conditioning. *Neuroscientist.* 2005;11(3):217-227.
- Dow RS, Moruzzi G. *The Physiology and Pathology of the Cerebellum.* Minneapolis, MN: University of Minnesota, Colwell Press; 1958.
- Hubbard DR, Berkoff GM. Myofascial trigger points show spontaneous needle EMG activity. *Spine (Phila Pa 1976).* 1993;18(13):1803-1807.
- Rissén D, Melin B, Sandsjö L, Dohms I, Lundberg U. Surface EMG and psychophysiological stress reactions in women during repetitive work. *Eur J Appl Physiol.* 2000;83(2-3):215-222.
- Critchley HD, Mathias CJ, Josephs O, et al. Human cingulate cortex and autonomic control: converging neuroimaging and clinical evidence. *Brain.* 2003;126(Pt 10):2139-2152.
- Oppenheimer SM, Gelb A, Girvin JP, Hachinski VC. Cardiovascular effects of human insular cortex stimulation. *Neurology.* 1992;42(9):1727-1732.
- Critchley HD, Melmed RN, Featherstone E, Mathias CJ, Dolan RJ. Brain activity during biofeedback relaxation: a functional neuroimaging investigation. *Brain.* 2001;124(Pt 5):1003-1012.
- Nobre AC, Sebestyen GN, Gitelman DR, Mesulam MM, Frackowiak RS, Frith CD. Functional localization of the system for visuospatial attention using positron emission tomography. *Brain.* 1997;120(Pt 3):515-533.
- Mesulam MM. Spatial attention and neglect: parietal, frontal and cingulate contributions to the mental representation and attentional targeting of salient extrapersonal events. *Philos Trans R Soc Lond B Biol Sci.* 1999;354(1387):1325-1346.
- D'Argembeau A, Collette F, Van der Linden M, et al. Self-referential reflective activity and its relationship with rest: a PET study. *Neuroimage.* 2005;25(2):616-624.
- Binder JR, Frost JA, Hammcke TA, Bellgowan PS, Rao SM, Cox RW. Conceptual processing during the conscious resting state. A functional MRI study. *J Cogn Neurosci.* 1999;11(1):80-95.
- Mazoyer B, Zago L, Mellet E, et al. Cortical networks for working memory and executive functions sustain the conscious resting state in man. *Brain Res Bull.* 2001;54(3):287-298.
- McGuire PK, Pauleso E, Frackowiak RS, Frith CD. Brain activity during stimulus independent thought. *Neuroreport.* 1996;7(13):2095-2099.
- Shulman GL, Fiez JA, Corbetta M, et al. Common blood flow changes across visual tasks: II decrease in cerebral cortex. *J Cogn Neurosci.* 1997;9(5):648-663.
- Nater UM, Rohleder N. Salivary alpha-amylase as a non-invasive biomarker for the sympathetic nervous system: current state of research. *Psychoneuroendocrinology.* 2009;34(4):486-496.
- Chatterton RT Jr, Vogelsong KM, Lu YC, Ellman AB, Hudgens GA. Salivary alpha-amylase as a measure of endogenous adrenergic activity. *Clin Physiol.* 1996;16(4):433-448.
- Nater UM. *The Role of Salivary Alpha-amylase in Stress Research.* Göttingen, Germany: Cuvillier Verlag; 2004.
- Rohleder N, Nater UM, Wolf JM, Ehlert U, Kirschbaum C. Psychosocial stress-induced activation of salivary alpha-amylase: an indicator of sympathetic activity? *Ann N Y Acad Sci.* 2004;1032:258-263.
- Granger DA, Kivlighan KT, el-Sheikh M, Gordis EB, Stroud LR. Salivary alpha-amylase in biobehavioral research: recent developments and applications. *Ann N Y Acad Sci.* 2007;1098:122-144.
- Maquet P, Dive D, Salmon E, von Frenkel R, Franck G. Reproducibility of cerebral glucose utilization measured by PET and the [18F]-2-fluoro-2-deoxy-d-glucose method in resting, healthy human subjects. *Eur J Nucl Med.* 1990;16(4-6):267-73.